

# Guidance of Retrobulbar Injection With Real-time Tomographic Reflection

*Wilson M. Chang, MS, George D. Stetten, MD, PhD,  
Louis A. Lobes, Jr, MD, Damion M. Shelton, BA, BS,  
Robert J. Tamburo, BS*

**Objective.** Retrobulbar and peribulbar injections are common ophthalmologic procedures used to deliver anesthetics and other medications for ophthalmic therapy and surgery. These injections, typically performed without any type of guidance, can lead to complications that are rare but visually devastating. The needle may penetrate the optic nerve, perforate the globe, or disperse toxic quantities of drugs intraocularly, causing major visual loss. Sonographic guidance may increase the accuracy of the needle placement, thereby decreasing the incidence of complications. However, difficulties arise in coordinating the relative location of the image, the needle, and the patient. Real-time tomographic reflection is a new method for in situ visualization of sonographic images, permitting direct hand-eye coordination to guide invasive instruments beneath the surface of the skin. **Methods.** In this preliminary study, real-time tomographic reflection was used to visualize the eye and surrounding anatomic structures in a cadaver during a simulated retrobulbar injection. **Results.** The needle tip was easily followed as it was advanced into the retrobulbar space. **Conclusions.** The images presented in this preliminary study show the use of real-time tomographic reflection to visualize insertion of an invasive instrument into the human body. **Key words:** real-time tomographic reflection; retrobulbar injection; sonographic guidance; Sonic Flashlight; tomographic reflection.

## Abbreviations

HMD, head-mounted display; RTTR, real-time tomographic reflection

*Received March 1, 2002, from the Department of Bioengineering, University of Pittsburgh (W.M.C., G.D.S.), The Robotics Institute, Carnegie Mellon University (W.M.C., G.D.S., D.M.S.), and University of Pittsburgh Medical Center (W.M.C., L.A.L.), Pittsburgh, Pennsylvania. Revision requested April 4, 2002. Revised manuscript accepted for publication May 6, 2002.*

*We thank John B. Schumann, PhD (University of Pittsburgh School of Medicine) for use of the cadaver and the anatomy laboratory.*

*Address correspondence and reprint requests to Wilson M. Chang, MS, Department of Bioengineering, University of Pittsburgh, 761 Benedum Hall, Pittsburgh, PA 15261.*

**S**onography is often used to guide percutaneous procedures such as vascular access or biopsies. The needle may be held freehand with respect to the ultrasonic transducer or constrained to the plane of the sonographic slice by a guide. In either case, the operator must look away from the patient to see the sonographic screen and therefore must rely on a displaced sense of hand-eye coordination.

To address this problem, some researchers have explored methods for viewing the sonographic image, patient, instrument, and operator's hands in one environment. Head-mounted display (HMD) systems have been developed to display a sonographic image within the patient.<sup>1-3</sup> These systems track the location of the ultrasonic transducer relative to the HMD so that the sonographic image can be computed and displayed in

the HMD with the correct stereoscopic perspective and location. To the person wearing the HMD, the sonographic image appears within the patient at its actual physical location. Despite their promise, HMD systems have yet to overcome significant obstacles, including lag time, low resolution, limited field of view, weight, and expense. Furthermore, if multiple observers are cooperating in a procedure, each observer requires a separate HMD to observe the same in situ sonographic image.


Real-time tomographic reflection (RTTR) is a simpler method for displaying sonographic images in real time at their correct physical location within the patient.<sup>4</sup> Real-time tomographic reflection avoids some of the drawbacks of HMD systems but achieves a similar effect by fixing the relative geometry of the transducer, the display, and a half-silvered mirror to produce a virtual image of the sonographic image within the body. Each pixel in the sonographic image seems to emanate from its correct location. Thus the patient, the sonographic image, the instrument, and the operator's hands are merged into one environment for all observers looking through the half-silvered mirror. Because no positional tracking or head-mounted apparatus is required, the cost of equipping a sonographic machine with RTTR is relatively small. The resulting device, which we call the Sonic Flashlight, requires a minimal amount of additional computation to properly scale and locate the image on the screen, making the lag time nearly imperceptible. In addition to facilitating existing sonographically guided procedures, the Sonic Flashlight may help promote the use of sonography in procedures that are commonly performed without any sonographic guidance, such as retrobulbar and peribulbar injection. These particular procedures are used to deliver local pharmacologic agents behind the eye, including anesthetics and corticosteroids. Retrobulbar and peribulbar anesthesia are necessary for patients who are undergoing glaucoma and retinal surgery without general anesthesia. Although sonography is not typically used to guide these procedures, it has been used to study the location of the needle after placement. In that study, Birch et al<sup>5</sup> found that the needle shaft was seen to actually indent the globe in 14 of 25 patients, suggesting that better guidance might reduce complications.

Complications from retrobulbar and peribulbar injections are rare but visually devastating because of the severe consequences of perforating the globe or optic nerve with the needle. Perforation of the optic nerve or direct damage to the optic nerve parenchyma can result in immediate permanent blindness from combined central retinal artery and vein occlusion. When the globe is perforated, vitreous hemorrhage and retinal detachment may require emergency surgical intervention. For patients with retinal detachment secondary to inadvertent perforation of the globe, the visual prognosis is very grave, with most patients being legally blind at 20/400 or worse, even after multiple surgical interventions. It is not known how many patients in the United States have these complications, but the literature suggests that there are several hundred cases of ocular perforation per year.<sup>6-8</sup> Our motivation is summarized by Birch et al, who stated that "a false sense of security may occur when performing retrobulbar blocks using only anatomic landmarks."<sup>5</sup>

### Materials and Methods

The present Sonic Flashlight prototype consists of an ultrasonic transducer (5.0- to 7.0-MHz 50S Tringa Vet; Pie Medical, Maastricht, Belgium), a flat-panel field emissions display (FE524G1; PixTech, Santa Clara, CA), and a 30 × 25-cm, 4-mm-thick half-silvered mirror (60% reflectance; Evaporated Coatings Inc, Willow Grove, PA) shown in Figure 1. The ultrasonic transducer and


**Figure 1.** The handheld RTTR device consists of an ultrasonic transducer and a flat-panel monitor mounted on opposite sides of a half-silvered mirror at a fixed angle of 90°.



the flat-panel display are fixed at 90° on opposite sides of the mirror by a rigid mount. The video signal from the sonographic scanner is transmitted to a desktop computer (AMD Athlon, 1.2 GHz; AMD, Sunnyvale, CA), which performs the rotation, scale, and translation necessary to display the sonographic image at its correct size and position on the flat-panel display. Calibration of the Sonic Flashlight was achieved by aligning a water-filled balloon with its sonographic image through visual inspection.

The cadaver was a female of unrevealed age and cause of death. Simulated retrobulbar injection was performed via insertion of a 40-mm 25-gauge needle (Fig. 2). An ophthalmologist with no prior experience using the Sonic Flashlight performed 2 procedures. In the first procedure, the needle was passed tangentially to the globe and directed toward the orbital floor, simulating a retrobulbar injection. In the second procedure, the globe was intentionally perforated

**Figure 2.** Using the handheld RTTR device. The operator looks through the half-silvered mirror to guide a retrobulbar injection.

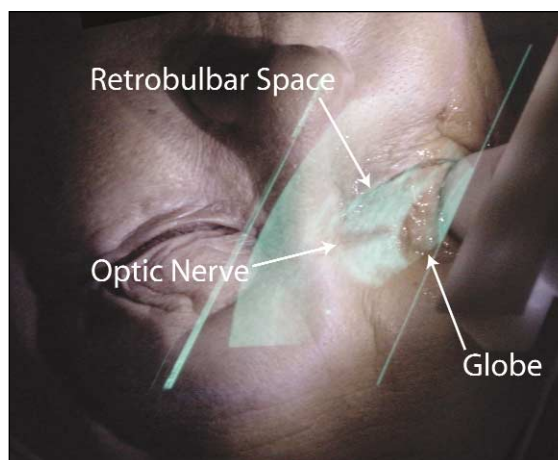


by aiming toward its center. In each procedure, the entry point was in the inferotemporal quadrant, one third of the way in from the lateral canthus. The Sonic Flashlight sonographic transducer was placed on the eyelid with the sonographic slice intersecting the globe and the needle.

## Results

With the use of the Sonic Flashlight, the globe, optic nerve, and retrobulbar space were visualized at their expected physical locations relative to the external anatomy (Fig. 3). The needle was inserted in the plane of the RTTR sonographic slice, allowing the needle tip to be followed throughout its entire path (Fig. 4). The needle was clearly seen passing inferior to the globe and into the retrobulbar space while easily avoiding surrounding structures. With the same technique, the needle puncturing the globe was also clearly visualized (Fig. 5). The operator found the device intuitive to use, although some hand fatigue was reported after 10 to 15 minutes. The system seemed to work best when the same person operated both the Sonic Flashlight and the needle.

**Figure 3.** Photograph taken from the viewpoint of the operator showing a sonogram of the orbit and the internal anatomic features. The globe, optic nerve, and retrobulbar space labeled above are easily identified.

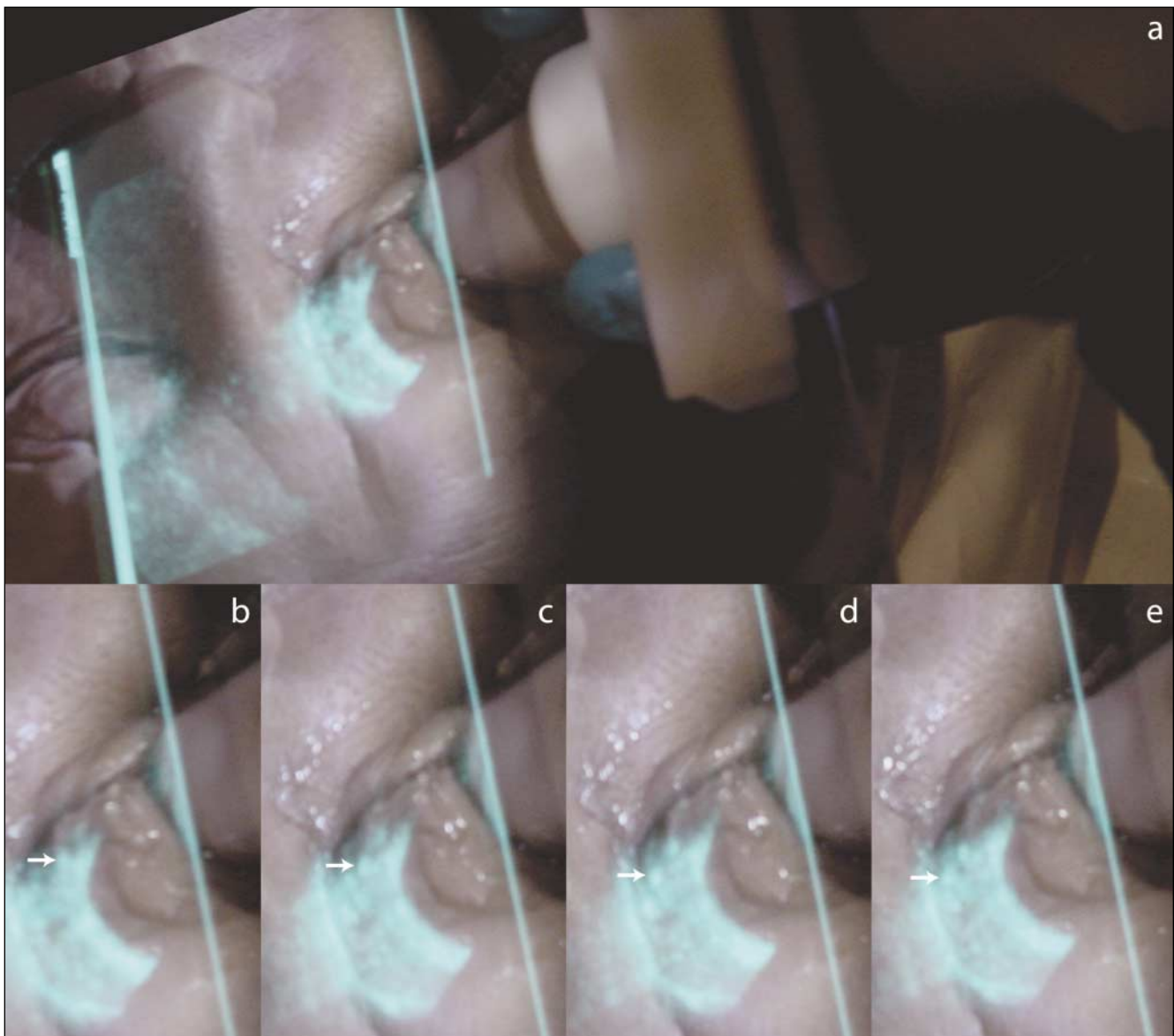


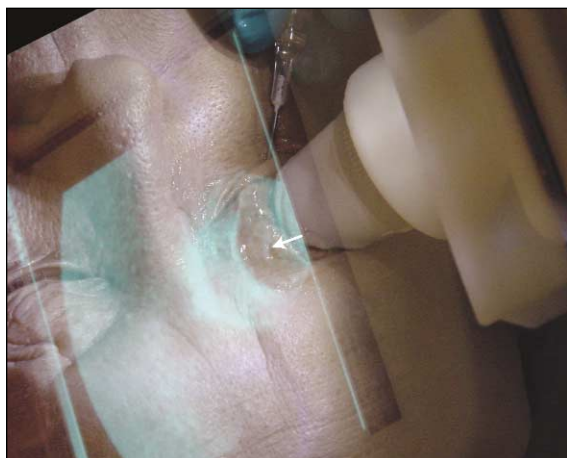
### Discussion

Previously we showed that RTTR could integrate human vision and sonographic images without any operator or instrument tracking but had not tested it on the human body. In this study we used RTTR to visualize the insertion of an invasive instrument into the human body. Our results are preliminary but quite promising. Unlike current sonographic guidance techniques in which natural hand-eye coordination is displaced, RTTR integrates the sonographic image into the

operator's view of the patient, allowing the operator to use innate hand-eye coordination. Furthermore, whereas conventional sonographic guidance uses a fixed in-plane guide to establish geometric relationships, RTTR allows the user to operate in or out of the plane of the sonographic slice. Real-time tomographic reflection provides the viewer with a three-dimensional sense of the sonographic slice's physical location, thereby imparting an understanding of the internal anatomy relative to the external anatomy as well as to the needle tip location.

**Figure 4.** Simulated retrobulbar injection guided by RTTR. **A** and **B**, Initial insertion of the needle. The arrow denotes the location of the needle tip. **C–E**, The needle is shown at its actual physical location as it is advanced into the retrobulbar space.





**Figure 5.** Perforation of the globe with a needle visualized by RTTR. The arrow denotes the location of the needle tip.

Our application to retrobulbar injection was motivated by the ease of performing this procedure on a cadaver. Although preventing complications from such procedures would make an enormous difference in individual cases, the frequency of such complications is relatively low. Beyond its application to the eye, we envision RTTR being used more commonly for outpatient and bedside procedures, including vascular access and biopsy, as well as more critical procedures such as thoracentesis and paracentesis.

We are currently planning the next version of our handheld prototype using a smaller, thinner, less reflective mirror as well as a smaller transducer. These changes will reduce the weight and associated hand strain. It should be noted that the external computer in our current prototype will not be necessary once RTTR is incorporated into a commercial sonography machine. In the future, a collapsible version of the Sonic Flashlight could be small enough to fit into the clinician's pocket, much as a stethoscope does today.

## References

1. State A, Livingston M, Garret W, et al. Technologies for augmented reality systems: realizing ultrasound-guided needle biopsies. Proceedings of SIGGRAPH 96; August 4–9, 1996; New Orleans, LA. In: Computer Graphics Proceedings, Annual Conference Series. New York, NY: Association for Computing Machinery; 1996:439–446.
2. Fuchs H, State A, Pisano E, et al. Towards performing ultrasound-guided needle biopsies from within a head-mounted display. Proceedings of Visualization in Biomedical Computing; Hamburg, Germany; September 22–25, 1996:591–600.
3. Sauer F, Khamene A, Bascle B, et al. Augmented reality visualization of ultrasound images: system description, calibration, and features. Proceedings of the IEEE and ACM International Symposium on Augment Reality; New York, NY: 2001:30–39.
4. Stetten G, Chib V. Overlaying ultrasound images on direct vision. *J Ultrasound Med* 2001; 20:235–240.
5. Birch A, Evans M, Redembo E. The ultrasonic localization of retrobulbar needles during retrobulbar block. *Ophthalmology* 1995; 102:824–826.
6. Wearne MJ, Flaxel CJ, Gray P, Sullivan PM, Cooling RJ. Vitreoretinal surgery after inadvertent globe penetration during local ocular anesthesia. *Ophthalmology* 1998; 105:371–376.
7. Hay A, Flynn HW Jr, Hoffman JI, Rivera AH. Needle penetration of the globe during retrobulbar and peribulbar injections. *Ophthalmology* 1991; 98: 1017–1024.
8. Duker JS, Belmont JB, Benson WE, et al. Inadvertent globe perforation during retrobulbar and peribulbar anesthesia: patient characteristics, surgical management, and visual outcome. *Ophthalmology* 1991; 98:519–526.